


Cyclosporine Before and Afters



Keith A. Hnilica DVM, MS
Diplomate ACVD
The University of Tennessee
www.UTSkinVet.org

NonSteroid Alternatives (NSAs)



www.itchnot.com

Atopica is a registered trademark of Novartis Animal Health US, Inc.

Successful Control With Atopica



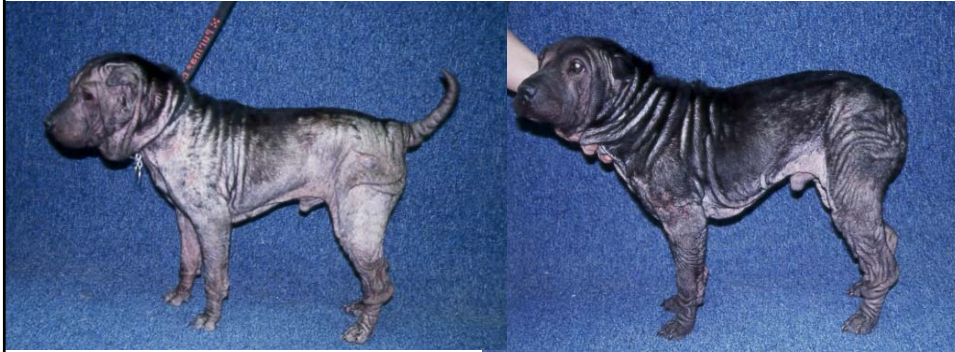Before treatment



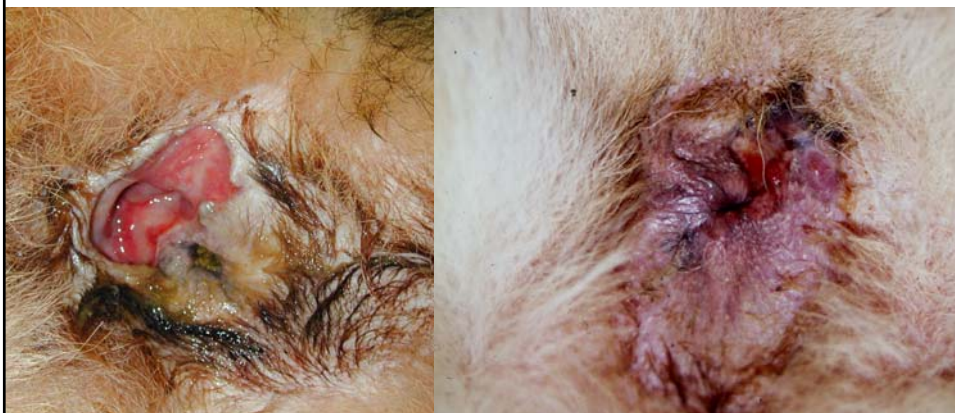After treatment

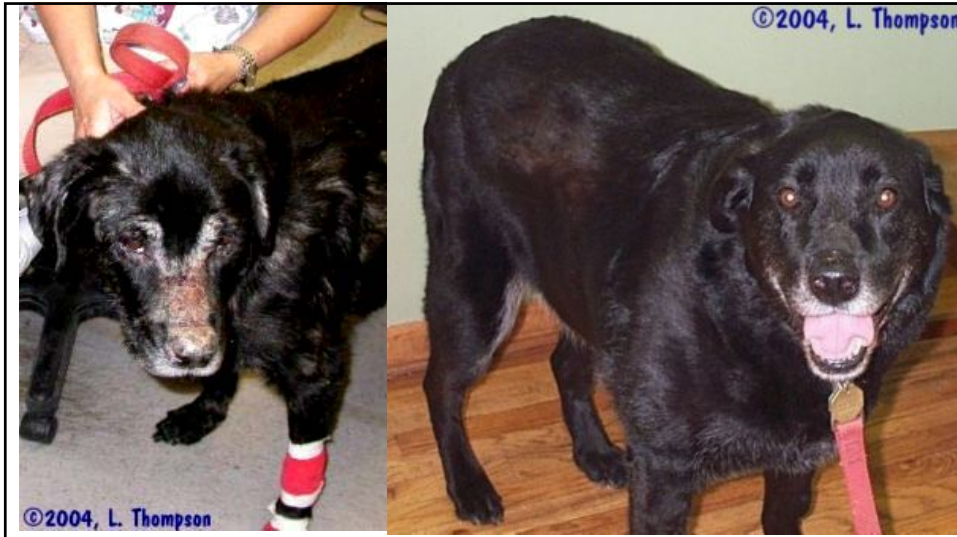Photos courtesy of Helen Power, DVM, Dipl ACVD

Cyclosporine

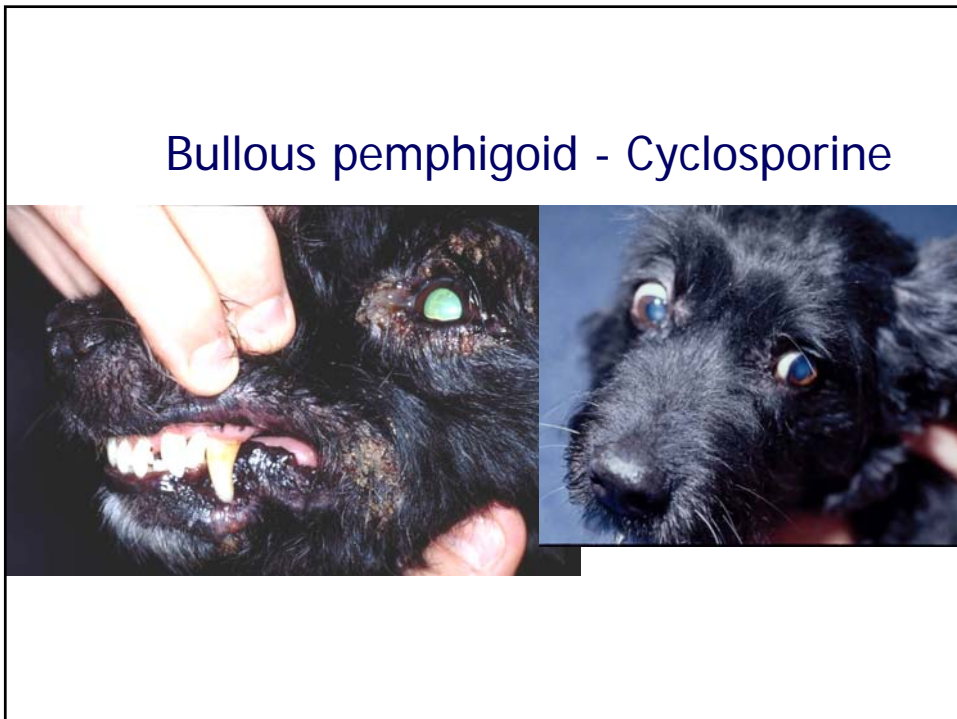

PA fistula - cyclosporine

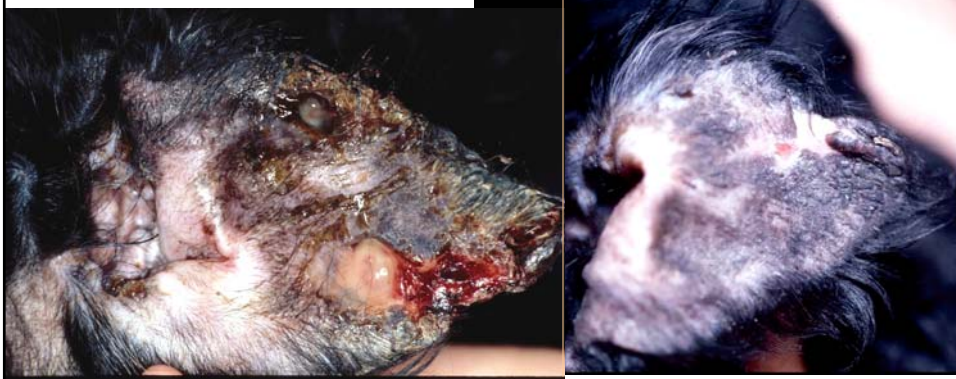



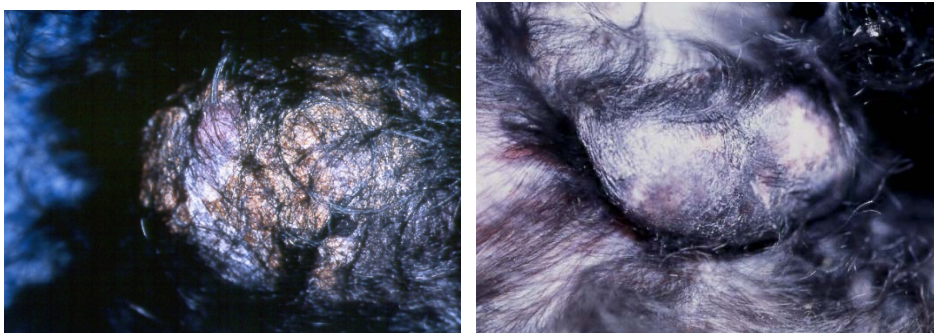Pemphigus



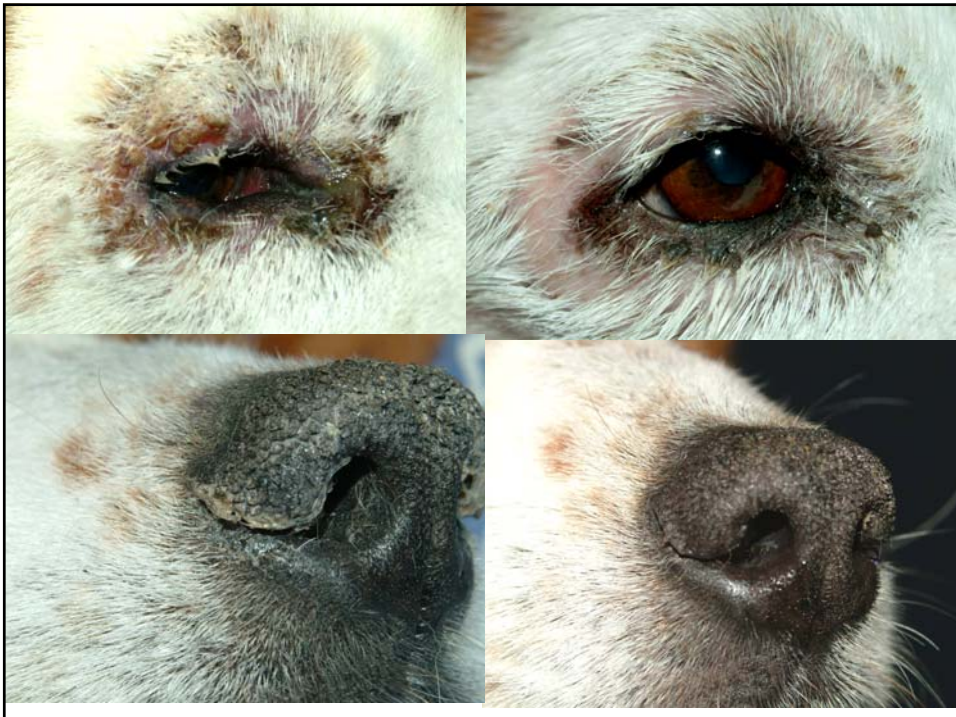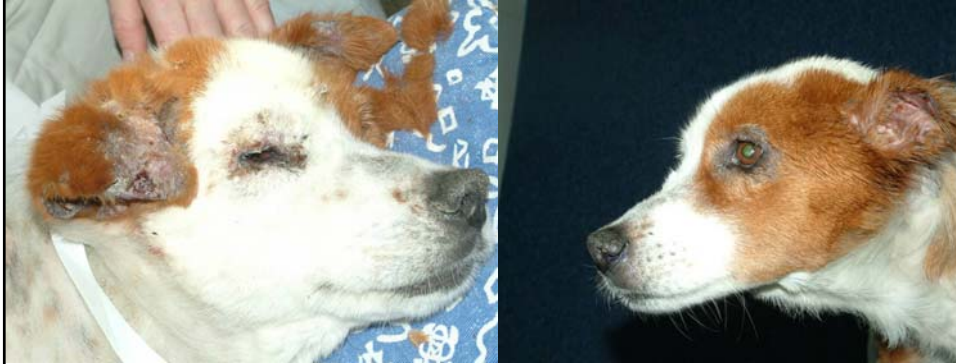Bullous pemphigoid - Cyclosporine

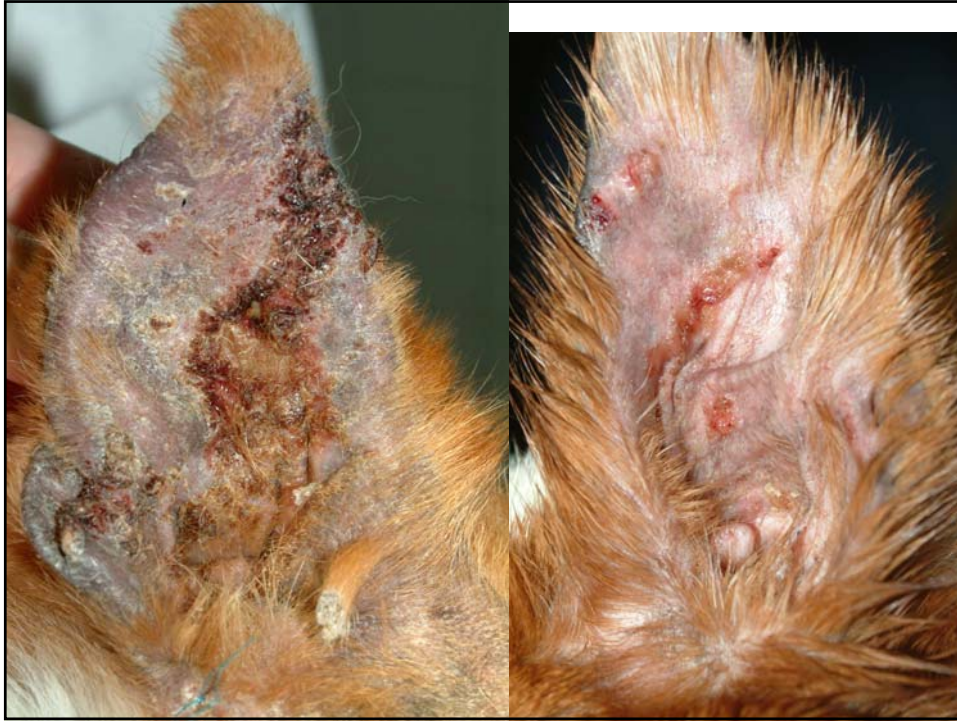

Bullous pemphigoid - Cyclosporine

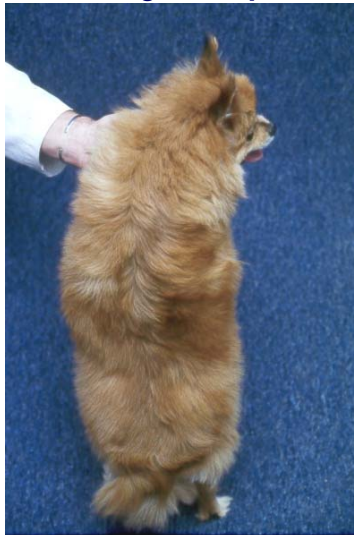
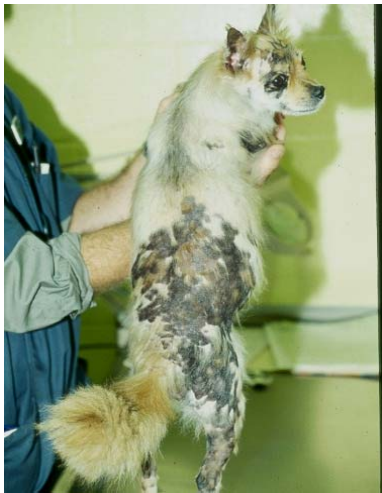
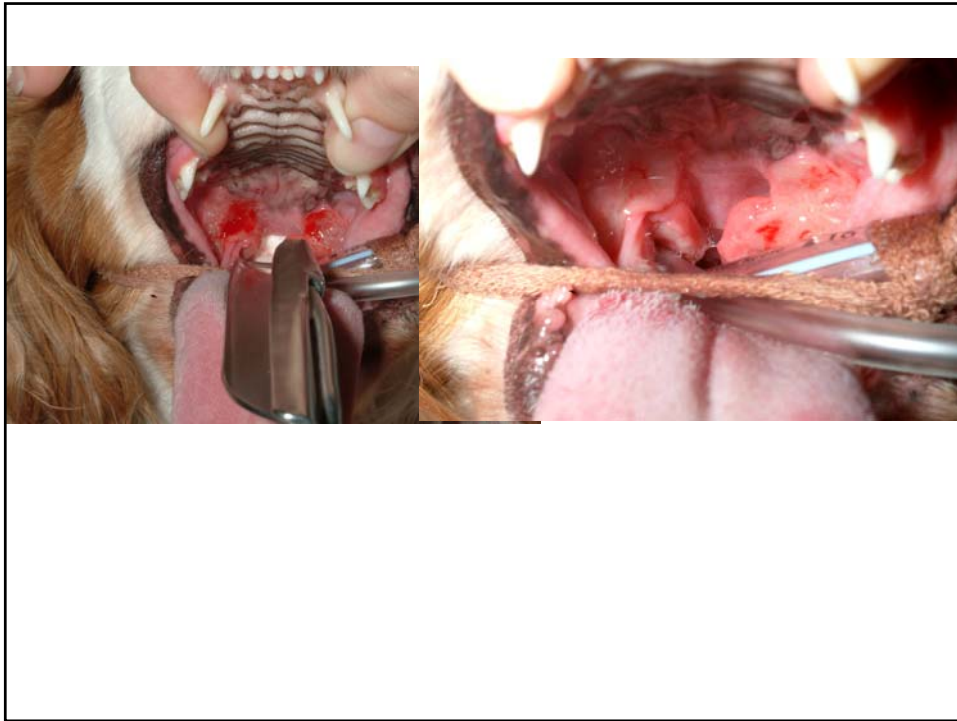
Lupus and cyclosporine (early)



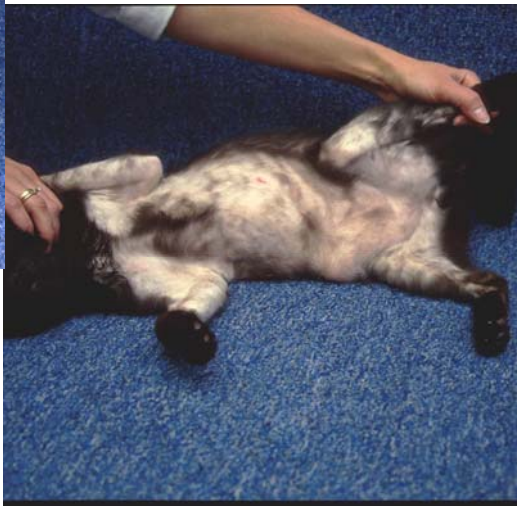

Erythema Multiforme - cyclosporine

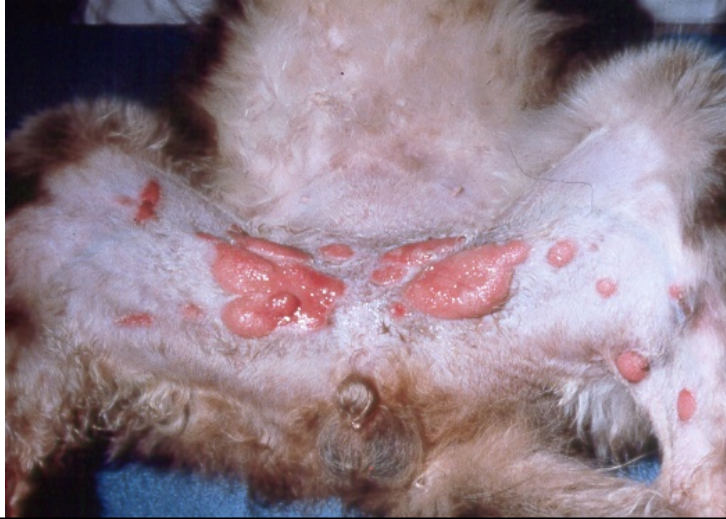



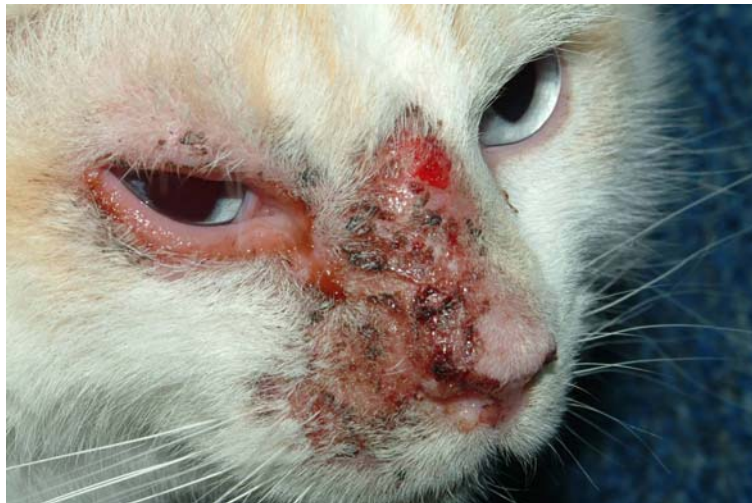Idiopathic Pruritus - Cyclosporine



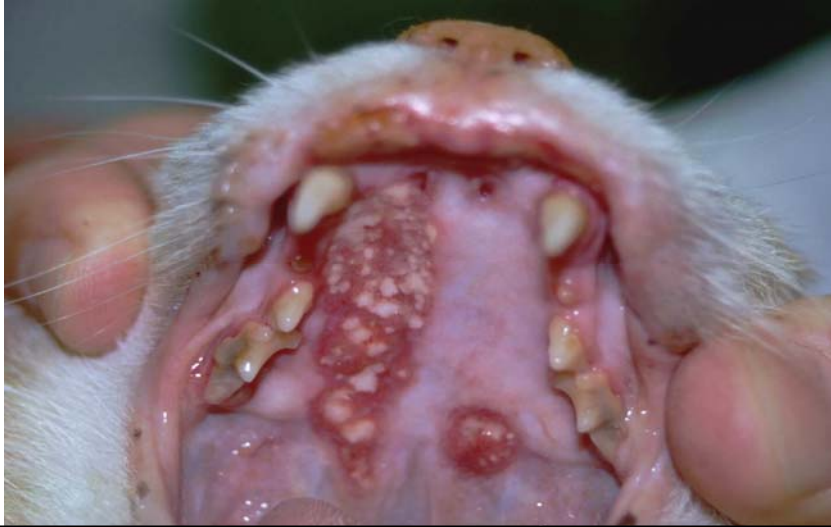Eosinophilic Granuloma



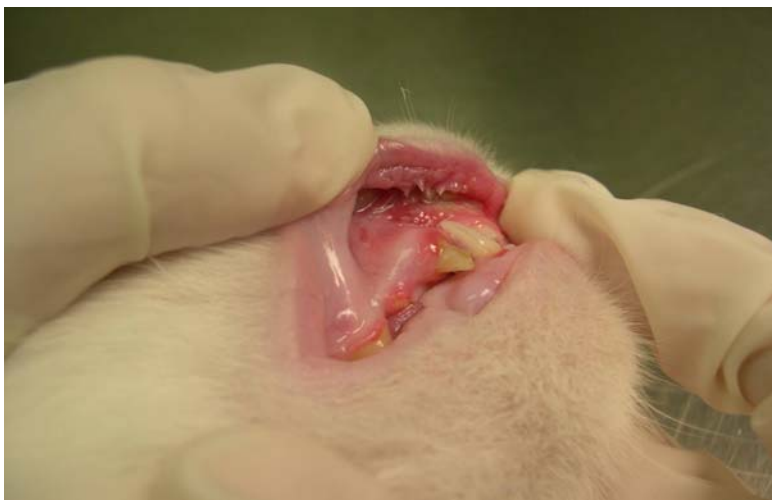Eosinophilic Granuloma



Eosinophilic Granuloma

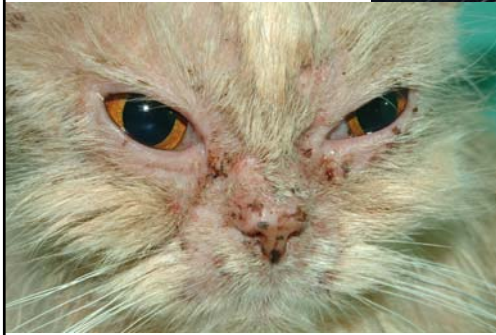

Stomatitis



D. Mawby

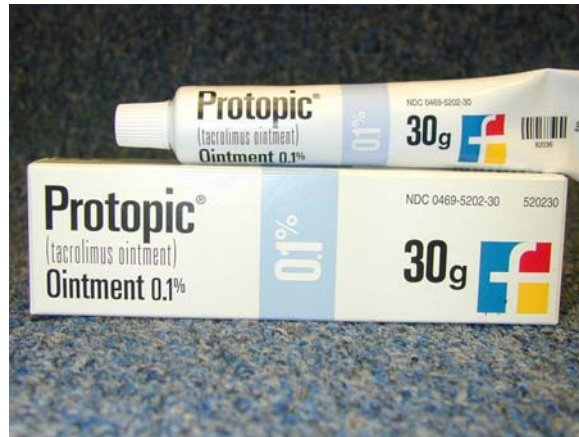Pemphigus



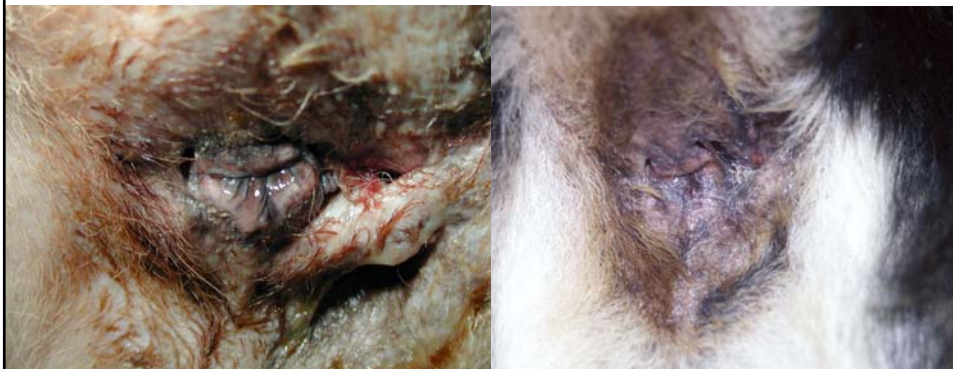Arthritis improved while taking Atopica???



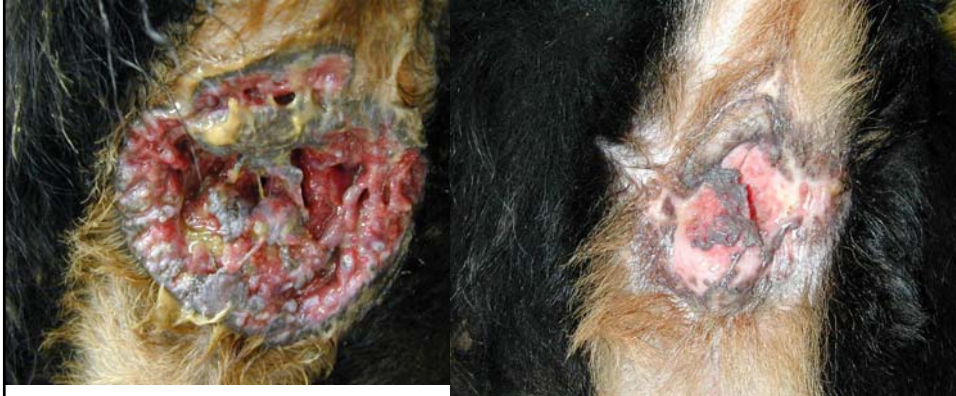Tacrolimus ointment



"Indy" and Protopic^R

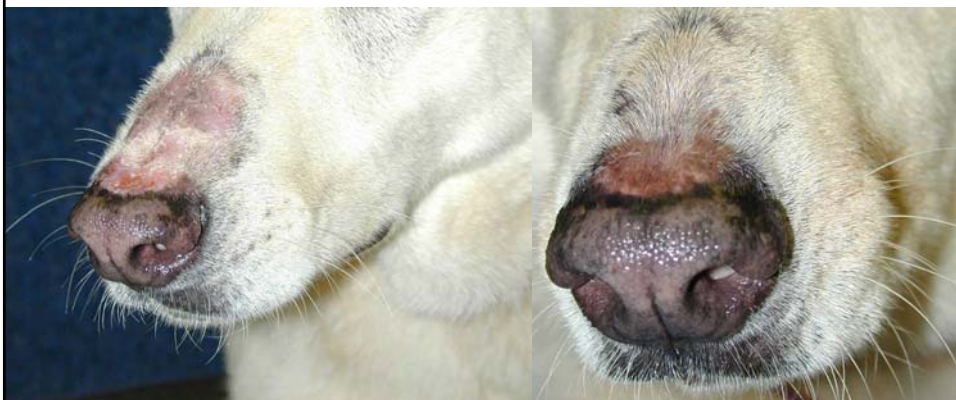

"Timber" and Protopic[®]

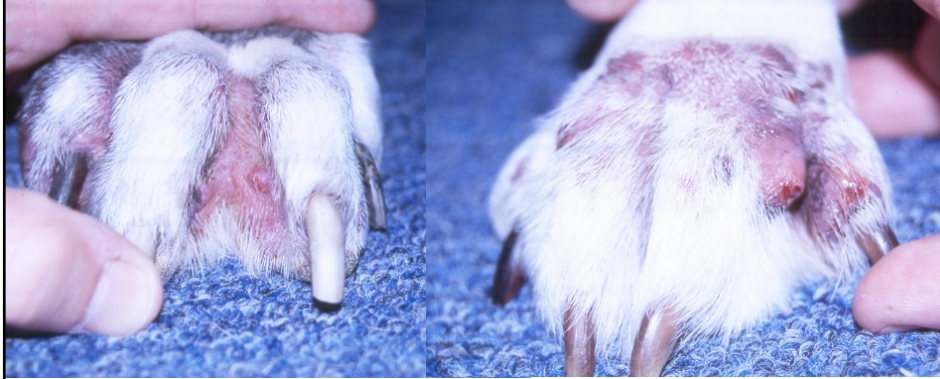

Added Prednisone x 4wks

DLE - tacrolimus



Interdigital Pyogranuloma/bullae



Cyclosporins/Tacrolimus

Allergic Dermatitis

Discoid Lupus

Pemphigus

Bullous pemphigoid

Systemic Lupus

Sebaceous Adenitis

Granulomatous
dermatoses

Psoriasis

Actinic dermatitis

Dermatomyositis

Alopecia X

Vasculitis

Urticaria

Rheumatoid arthritis

Sweet's syndrome

Panniculitis

Erythema multiforme

Hypereosinophilic
syndrome

Eosinophilic granulomas

Scleroderma

Senile pruritus

VKH

Vitiligo

Poison Ivy

AIHA

Colitis

Organ Transplants

Perianal fistulas

Interdigital pyogranuloma

Persian Facial Dermatitis

Feline Stomatitis